



Sodium Hypochlorite Accidentally Extruded Beyond the Apical Foramen

Su-Hsin Wang¹, Ming-Pang Chung¹, Jen-Chan Cheng², Chih-Ping Chen¹, and Yi-Shing Shieh^{1*}

¹*Division of Endodontics;* ²*Division of oral and maxillofacial surgery, Department of Dentistry, Tri-Service General Hospital, National Defense Medical Center, Taipei, Taiwan, Republic of China*

Sodium hypochlorite (NaOCl) is routinely used as an endodontic irrigant to clean and disinfect the root canal system. Although it is generally believed safety, the tissue toxicity of NaOCl cannot be ignored. This report describes two cases of accidental extrusion of sodium hypochlorite solution into the periradicular tissues during root canal instrumentation. The literatures were reviewed to explore possible etiologies and possible complications. Diagnostic criteria for sodium hypochlorite accidents and strategies to mitigate the risk are also suggested.

Key words: root canal irrigants, root canal irrigation, sodium hypochlorite accident

INTRODUCTION

Mechanical instrumentation alone is insufficient to achieve completely cleaning and shaping of root canals during endodontic therapy due to the complexities of the root canal system.^{1,2} Various investigations have demonstrated that irrigating solutions during shaping procedures are required to assist cleaning and disinfection of root canals.³⁻⁵ Sodium hypochlorite (NaOCl) has been used for more than 60 years as an endodontic irrigant and remains one of the most frequently used irrigants in root canal therapy.¹ Advantages of sodium hypochlorite include the strong antibacterial properties and its unique ability to dissolve organic tissue. It can also lower the concentration of microorganism significantly in many documented studies.⁶⁻¹¹ In addition, NaOCl can serve as a lubricant and facilitate removal of dentine debris during instrumentation.⁷ However, various studies have revealed that sodium hypochlorite may damage tissues.¹²⁻¹⁷ This paper describes two cases in which sodium hypochlorite was extruded beyond the apical foramina during cleaning and shaping procedures, and strategies to prevent the risk of this adverse event were suggested.

CASE REPORT

CASE 1

A 59-year-old female was referred from the local dental clinic for endodontic treatment of the left upper canine (tooth #23). The access cavity of tooth #23 was temporarily restored with Cavition® (GC Asahi Corp, Aichi, Japan). We performed intraoral examinations including percussion, palpation, and periodontal tests. Compared to neighboring teeth, the tooth #23 was slightly sensitive to palpation with mild pain to percussion. No pathological tooth mobility was found. Probing depths around tooth #23 were 3 mm, but bleeding on probing was noted. The initial periapical radiograph showed a widened, irregular periodontal ligament space compared to proximal teeth. (Fig. 1A) Moreover, a vague radiopaque image was noted in the apical third of tooth#23.

A diagnosis was made of symptomatic apical periodontitis of the left upper canine despite previous endodontic treatment. In addition, periradicular fenestration or over-instrumentation was suspected because tooth #23 was sensitive to palpation. After explaining the treatment plan with the patient, non-surgical root canal therapy of tooth #23 was initiated. Endodontic access via the previous access cavity was made under rubber dam isolation. Some obstructed gutta-percha segment in the apical region was observed under the microscope. To aid in debridement, the canal was frequently irrigated with copious 2.5% NaOCl delivered with a 25-gauge irrigation needle using a slow and gentle ejection motion. During the cleaning and shaping procedure, the patient experienced sudden pain and concurrent burning sensation in the left

Received: July 28, 2009; Revised: November 23, 2009;
Accepted: February 9, 2010

*Corresponding author: Yi-Shing Shieh, Department of Endodontics, Tri-Service General Hospital, National Defense Medical Center, No. 325, Sec. 2, Cheng-gong Road, Taipei 114, Taiwan, Republic of China. Tel: +886-2-87919276; Fax: +886-2-87919276; E-mail: ndmcyss@nhri.org.tw

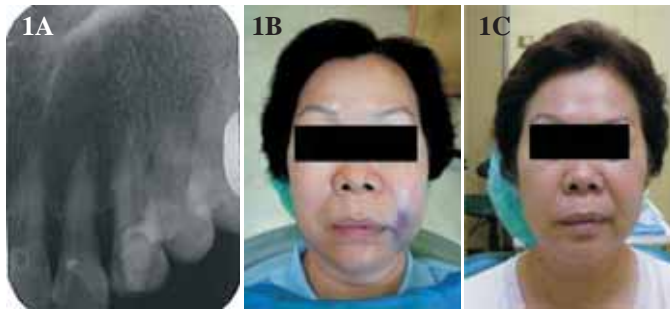


Fig. 1 (A) Initial radiograph showed no periapical lesion, but widened periodontal ligament space was observed around tooth #23. A radiopaque image was noted in the apical region of tooth #23. (B) Swelling of left midface extending to the orbital region and bruising of cheek occurred 2 days after extrusion of NaOCl. (C) Swelling and bruising resolved in 2 weeks with no other signs or symptoms.

midface region. The root canal filled with blood. A decision was made to terminate the procedure. Upon removal of the rubber dam, an obvious swelling of the patient's left midface was noted.

The root canal was irrigated with sterile saline and the access cavity was temporarily restored with a cotton pellet and Caviton®. The pain was resolved completely and the patient was given home care instruction. A complete explanation of the clinical events that occurred in re-treating tooth #23 was also provided to the patient. An analgesic was prescribed (diclofenac 50mg tid pc for 3 days) and follow-up appointment was made. The patient returned to the clinic in 2 days with left midfacial swelling, which extended to the orbital region, and bruising of the cheek. (Fig. 1B) The patient denied any burning sensation or pain. She was prescribed an oral antibiotic (Amoxicillin 250 mg q8h for 3 days) to prevent the possible infection. The swelling and bruising disappeared after 2 weeks without clinical sign or symptom. (Fig. 1C)

Root canal treatment of tooth #23 was restarted. On microscopic inspection, a perforation (associated with the original endodontic treatment) was noted near the apical region (3 mm bucco-coronally from the radiographic apex). The presence of the perforation was confirmed using the Endometer (Root Zx) test. Sensitivity and bleeding were noted on touching the perforated area with a paper point. The perforation was the most likely cause for the inadvertent extrusion of the sodium hypochlorite solution into the periradicular tissues during irrigation. One month later, the original canal of tooth #23 was obturated with gutta-percha and sealer (Kerr Corp, MI, USA) to the

perforation site using vertical compaction technique. The patient was advised for periodic follow-up.

CASE 2

A 69-year-old female presented to our clinic with spontaneous pain in the right mandibular region of several days' duration. Clinical examination of the soft tissues of the affected area showed no signs of scarring or fistula. Teeth #45 and #47 (right mandibular second bicuspid and second molar) had been restored with a Maryland bridge for several years. Compared with adjacent teeth, tooth #47 was sensitive to cold, heat, and percussion. No pathological tooth mobility was found. Probing depths around teeth #45 and #47 were 3 mm, but bleeding on probing was noted. A gap was detected by dental explorer around the crown margin of tooth #47. Periapical radiograph showed no periapical lesion although a radiolucent shadow was seen in distal proximal cervical area below the margin of a restoration. (Fig. 2A)

A diagnosis was made of irreversible pulpitis of tooth #47 with acute apical periodontitis because of secondary caries with pulpal involvement. After explaining the treatment plan with the patient, emergency endodontic treatment of the tooth #47 was initiated. Access cavity preparation was performed under block anesthesia, and pulp tissues were extirpated. Sequential cleaning and shaping were performed with rubber dam isolation. Root canal system was frequently irrigated with copious 2.5% NaOCl delivered with a 25-gauge irrigation needle using a slow and gentle ejection motion. During this procedure, the patient experienced sudden severe pain and bloody exudate rapidly filled the pulp chamber.

The patient's symptoms resolved completely after the root canal was irrigated with sterile saline. The access cavity was temporarily restored with a cotton pellet and Caviton®. The patient was given home care instruction and a complete explanation of the clinical events that occurred in treating tooth #47. She was prescribed an oral analgesic (diclofenac 50mg tid pc for 3 days) and antibiotic (Amoxicillin 250 mg q8h for 3 days) for pain and infection control. The patient returned to the clinic in 2 weeks with a bruise in her right mandibular area. (Fig. 2B) She explained that swelling and bruising in this region occurred after leaving the clinic. The patient indicated she believed these sequelae were normal and took the medication as prescribed. Subsequently, the signs and symptoms improved gradually. No numbness or pain on palpation of the affected region was noted at this follow-up appointment. One week later, the bruising had disappeared without other signs or symptoms. (Fig. 2C)

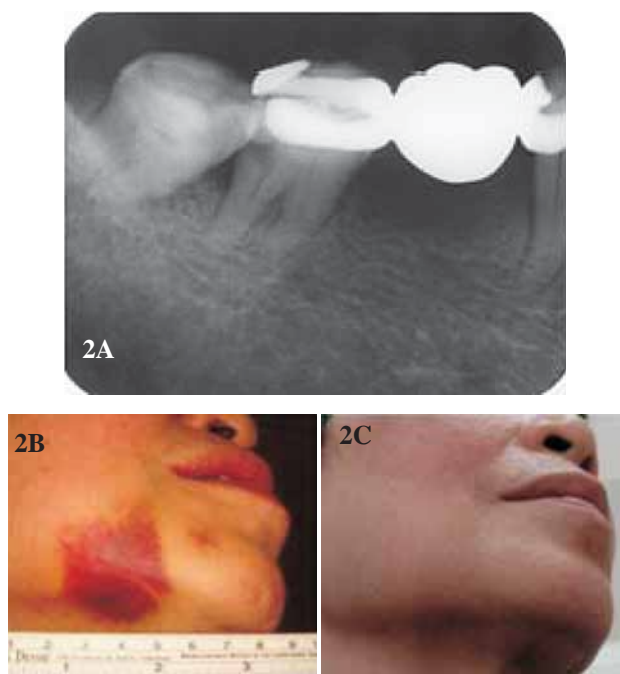


Fig. 2 (A) Initial radiograph of tooth #47 showed no periapical lesion, but a radiolucent area was seen in the distal proximal cervical area below the margin of an old restoration. (B) Patient returned to the clinic 2 weeks later with bruising (approximately 3 × 4 cm) of her right mandibular area. (C) One week later, the bruising had resolved with no other signs or symptoms.

Root canal instrumentation was completed and the canals were obturated with gutta-percha and Kerr sealer to the ideal working length using vertical condensation. No perforation or other iatrogenic complications occurred during the treatment course.

DISCUSSION

Effective irrigation plays an important role in successful root canal treatment. NaOCl (0.5-5.25%) remains the most frequently used irrigant in endodontic therapy.¹⁴ In addition to its lubricant and dissolvent activities, which assist in cleaning and shaping procedures, NaOCl has strong bactericidal activity for disinfection of root canal.⁶⁻¹¹ NaOCl is a strong base (pH 11) that reacts with amino acids forming water and salt. Moreover, a chloramination reaction interferes with the metabolism of bacteria.^{10,11} Because of these properties, NaOCl possesses efficient organic tissue-dissolving capability and antimicrobial activity.

Although NaOCl is used worldwide as an intracanal irrigant for root canal disinfection and debridement, its

toxicity to organic tissues is also high.^{14,16,19} Improper use of NaOCl during endodontic treatment may result in undesirable outcomes including severe symptoms and complications. Similar NaOCl-related complications to those described in the present case studies have been reported in the literatures.¹²⁻²³ Generally, complications from NaOCl accidents have included eyes burning,²⁰ allergic reactions,²¹ injection into maxillary sinus,²² pain and swelling after introduction beyond the tooth apex,^{12-14,17,18} nerve damage¹⁵ and airway obstruction.²³ According to previous reports, extrusion of NaOCl solution into periradicular tissues during root canal treatment occurs more readily when there is a perforation or wide apex in the treated tooth combined with uncontrolled irrigation force.¹³ In most cases, patients only need proper home care instruction and antibiotic therapy for prevention of secondary infection.¹³ Typically, signs and symptoms such as pain, swelling, and bruising usually disappear in a few weeks and seldom cause permanent complications such as neurological damage.¹⁶

When NaOCl is inadvertently forced into the periapical tissues, the sequence of injury seems to follow a typical pattern. According to Hülsmann criteria,¹³ the diagnostic for a NaOCl accident include the following: 1) acute pain, swelling and redness; 2) bruising; 3) progressive swelling involving the infraorbital area or mouth angle; 4) profuse hemorrhage often manifesting intraorally from the orifice of the tooth; 5) numbness or weakness of the facial nerve; and 6) secondary infection, sinusitis and cellulitis. In our case reports, distinguishing features included swelling, redness, and bruising. Especially in the first case report, the patient exhibited most of the features described.

Based on our experience, the patient should be fully informed when a NaOCl accident occurs, and found out the possible etiology. Treatment should focus on the principles of minimizing swelling, controlling pain and preventing secondary infection. Pain control is very important; local anesthesia or oral analgesics may be helpful to relief pain. External compression with cold packs to the local area is recommended to alleviate discomfort and minimize edema. Cold packs should be replaced by warm compresses for several days. Antibiotics may be needed to prevent the possibility of secondary infection. In serious cases, referral to a medical center or surgical intervention may be needed.

To prevent NaOCl accidents, initial radiographs should be taken to verify the length of the canal. Careful evaluation of the integrity of individual canals is essential. It is important to always avoid binding the irrigation

needle in the canal wall when NaOCl solution injection. A gentle ejection motion should be used instead of a more violent injection movement.

Despite taking preventive steps, NaOCl accidents may still occur with potential complications due to the tissue toxicity this irrigant. Safer and better endodontic irrigants are needed. Several studies have evaluated the clinical safety of different irrigants or different concentrations of NaOCl used in endodontic treatment. Naenni et al.⁹ compared several irrigants used in endodontic irrigation including 1% NaOCl, 10 % chlorhexidine, 3% and 30% hydrogen peroxide, 10% peracetic acid, 5% dichloroisocyanurate (NaDCC), and 10% acetic acid. Results indicated that only NaOCl dissolves necrotic pulp tissues. Baumgartner⁷ evaluated several concentrations of NaOCl as root canal irrigant and showed that concentrations of 5.25%, 2.5% and 1.0% completely remove pulpal remnants and predentin from uninstrumented canal wall surfaces. Some reports⁸ showed that using a higher concentration of NaOCl shortens the time needed for dissolving tissues, however, tissue toxicity is increased. Other researchers have revealed that the antimicrobial activity of 2% chlorhexidine gel is superior to NaOCl^{24,25} although 2% chlorhexidine gel cannot dissolve necrotic pulp tissue.

CONCLUSION

This report serves as a reminder of the potential risks of NaOCl solution used as an endodontic irrigant and describes the many potential complications of NaOCl extrusion into periradicular tissues. Also described in the present report are strategies to minimize the occurrence of NaOCl accidents and sequential procedures for treatment. Before starting root canal treatment, clinicians should carefully inspect canal integrity from initial radiographs. When NaOCl is selected as an endodontic irrigant, a gentle ejection motion is required at all the times during the procedure. Low, constant pressure should be used with the injection needle slightly withdrawn from any binding point. Proper pre-treatment management such as use of protective glasses and cover cloths is essential as is rubber dam isolation to protect intraoral tissues from the damaging effects of NaOCl.

REFERENCES

1. Zehnder M. Root canal irrigants. *J Endod.* 2006 May;32:389-398.
2. Peters OA, Laib A, Gohring TN, Barbakow F. Changes in root canal geometry after preparation assessed by high-resolution computed tomography. *J Endod* 2001;27:1-6.
3. Love RM. Enterococcus faecalis: a mechanism for its role in endodontic failure. *Int Endod J.* 2001;34:399-405.
4. McDonnell G, Russell AD. Antiseptics and disinfectants: activity action, and resistance. *Clin Microbiol Rev.* 1999;12:147-179.
5. Vianna ME, Gomes BP, Berber VB, Zaia AA, Ferraz CC, de Souza-Filho FJ. In vitro evaluation of the antimicrobial activity of chlorhexidine and Sodium hypochlorite. *Oral Surg Oral Med Oral Pathol Oral Radiol Endod.* 2004;97:79-84.
6. Radcliffe CE, Potouridou L, Qureshi R, Hababeh N, Qualtrough A, Worthington H, Drucker DB. Antimicrobial activity of varying concentrations of Sodium hypochlorite on the endodontic microorganisms *Actinomyces israelii*, *A. naeslundii*, *Candida albicans* and *Enterococcus faecalis*. *Int Endod J.* 2004;37:438-466.
7. Baumgartner JC, Cuenin PR. Efficacy of several concentrations of sodium hypochlorite for root canal irrigation. *J Endod.* 1992;18:605-612.
8. Spanó JC, Barbin EL, Santos TC, Guimarães LF, Pécora JD. Solvent action of sodium hypochlorite on bovine pulp and physico-chemical properties of resulting liquid, *Braz Dent J.*2001;12:154-157.
9. Naenni N, Thoma K, Zehnder M. Soft tissue dissolution capacity of currently used and potential endodontic irrigants. *J Endod.* 2004;30:785-787.
10. Clarkson RM, Moule AJ. Sodium hypochlorite and its use as an endodontic irrigant. *Aust Dent J.* 1998;43:250-256.
11. Estrela C, Estrela CR, Barbin EL, Spanó JC, Marchesan MA, Pécora JD. Mechanism of action of sodium hypochlorite. *Braz Dent J.* 2002;13: 113-117.
12. Gatot A, Arbelle J, Leiberman A, Yanai-Inbar I. Effects of sodium hypochlorite on soft tissues after its inadvertent injection beyond the root apex. *J Endod.* 1991;17:573-574.
13. Hülsmann M, Hahn W. Complications during root canal irrigation — literature review and case reports. *Int Endod J.*2000;33:186-193.
14. Gernhardt CR, Eppendorf K, Kozłowski A, Brandt M. Toxicity of concentrated sodium hypochlorite used as an endodontic irrigant. *Int Endod J.* 2004;37:272-280.
15. Witton R, Henthorn K, Ethunandan M, Harmer S, Brennan PA. Neurological complications following extrusion of sodium hypochlorite solution during root

- canal treatment. *Int Endod J.* 2005;38:843-848.
16. Gursoy UK, Bostanci V, Kosger HH. Palatal mucosa necrosis because of accidental sodium hypochlorite injection instead of anaesthetic solution. *Int Endod J.* 2006;39:157-161.
 17. Motta MV, Chaves-Mendonca MA, Stirton CG, Cardozo HF. Accidental injection with sodium hypochlorite: report of a case. *Int Endod J.* 2009;42:175-182.
 18. Fuentes de Sermeño. Tissue damage after sodium hypochlorite extrusion during root canal treatment. *Oral Surg Oral Med Oral Pathol Oral Radiol Endod.* 2009;108:e46-e49.
 19. Pashley EL, Birdsong NL, Bowman K, Pashley DH. Cytotoxic effects of sodium hypochlorite on vital tissue. *J Endod.* 1985;11:525-528.
 20. Ingram TA. Response of the human eye to accidental exposure to sodium hypochlorite. *J Endod.* 1990;16:235-238.
 21. Kaufman AY, Keila S. Hypersensitivity to sodium hypochlorite. *J Endod.* 1989;15:224-229.
 22. Ehrlich DG, Brian JD Jr, Walker WA. Sodium hypochlorite accident: Inadvertent injection into the maxillary sinus. *J Endod.* 1993;19:180-182.
 23. Bowden JR, Ethunandan M, Brennan PA. Life-threatening airway obstruction secondary to hypochlorite extrusion during root canal treatment. *Oral Surg Oral Med Oral Pathol Oral Radiol Endod.* 2006;101:402-404.
 24. Dametto FR, Ferraz CC, de Almeida Gomes BP, Zaia AA, Teixeira FB, de Souza-Filho FJ. In vitro assessment of the immediate and prolonged antimicrobial action of chlorhexidine gel as an endodontic irrigant against *Enterococcus faecalis*. *Oral Surg Oral Med Oral Pathol Oral Radiol Endod.* 2005;99:768-772.
 25. Ercan E, Ozekinci T, Atakul F, Gül K. Antibacterial activity of 2% chlorhexidine gluconate and 5.25% sodium hypochlorite in infected root canal: In vivo study. *J Endod.* 2004;30:84-87.